

CASE REPORT

ONE-STEP-APEXIFICATION OF AN IMMATURE TOOTH USING MTA: A CASE REPORT

Authors:

Dinesh Kamath¹
Pauline Susan Paulose²
Ajay P. Joseph³
Gis George⁴
Anitha Viswanadhan⁵

Professor and Head¹
Department of Conservative Dentistry
and Endodontics
Indira Gandhi Institute of Dental Sciences,
Nellikuzhi P. O., Kothamangalam 686 691, Kerala

Senior Lecturer^{2,4,5}
Department of Conservative Dentistry
and Endodontics
Indira Gandhi Institute of Dental Sciences,
Nellikuzhi P. O., Kothamangalam 686 691, Kerala

Reader³
Department of Conservative Dentistry
and Endodontics
Indira Gandhi Institute of Dental Sciences,
Nellikuzhi P. O., Kothamangalam 686 691, Kerala

Address for correspondence:
Dr. Pauline Susan Paulose
Senior Lecturer
Department of Conservative Dentistry
and Endodontics
Indira Gandhi Institute of Dental Sciences,
Nellikuzhi P. O., Kothamangalam 686 691, Kerala
Email: paulinepaulose272@gmail.com

ABSTRACT

Apexification is a treatment protocol well recognized and accepted by clinicians worldwide for the management of an immature tooth with necrotic pulp. Traditionally, calcium hydroxide has been the material of choice for the apexification of immature permanent teeth. But the disadvantages of long treatment time, fracture of teeth and incomplete calcification of apical bridge have led to the development of other biomimetic materials such as MTA. This case report is based on the successful treatment of a 21-year-old female patient with an immature open apex, with MTA for apexification procedure.

Key words: Apexification, mineral trioxide aggregate, open apex, apical barrier, one-visit.

J Odontol Res 2020;8(2)23-6.

INTRODUCTION

A tooth with an immature open apex presents the problems of overfilling and poor apical seal of obturation¹. Cleaning and disinfection of the infected root canal cannot be done with standard root canal protocols. An apical barrier is much desired to enable optimal obturation of the root canal system. Calcium hydroxide has been used successfully to effect an apical barrier formation^{2,3} i.e. apexification in these teeth. Apexification can be defined as a 'method to induce a calcified barrier in a root with an open apex or the continued apical development of teeth with incomplete roots and a necrotic pulp' (American Association of Endodontists 2003)⁴. Apexification with calcium hydroxide is the most common treatment option for necrotic teeth with immature roots. However, calcium hydroxide shows certain limitations like incomplete calcification of dentinal bridge and prolonged treatment duration which may present problems with patient compliance. MTA has been described as a good material this procedure due to its good canal sealing property, biocompatibility and ability to promote dental pulp and periradicular tissue regeneration. It has been reported that MTA root fillings placed at the cemental canal limit showed better results than overfilling's.^{5,6} The aim of this report was to present the short-term follow-up of a nonvital teeth and open root apex which was managed with an MTA apical plug technique.

CASE REPORT

A 21 year- old female presented to the department of conservative dentistry and endodontics, with discolored upper left central incisor that is tooth number¹¹. On asking leading questions patient gave no history of pain or discomfort associated with¹¹. Patient had noticed the discoloration since two years. The patient had history of trauma ten years before. Clinical examination revealed a discolored central incisor and radiographic examination shown a wide open apex and a radiolucent area (fig.1). A diagnosis of immature non-vital tooth with periapical radiolucency was made. A one step apexification preceded by canal disinfection for two weeks with calcium hydroxide was planned for this tooth.

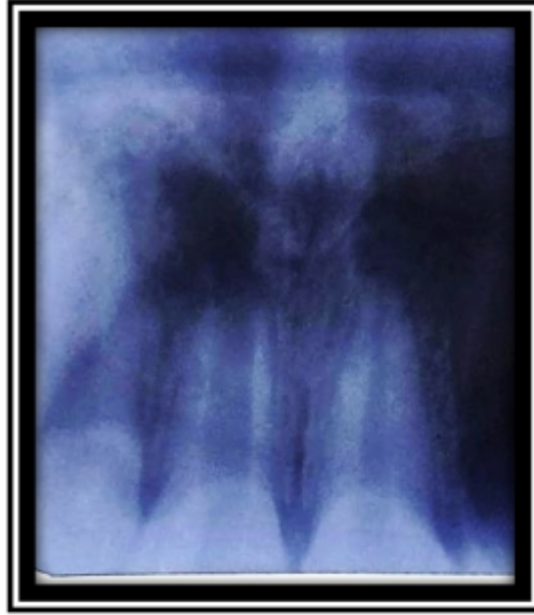


Fig.1

After application of rubber dam and access cavity preparation, working length was obtained with 80k file which was 14 mm. Cleaning and shaping of the root canal was done with irrigation with 5.25% of sodium hypochlorite, a slurry of calcium hydroxide mixed with Chlorhexidine and was placed in the canal and temporized. The patient was asked to return after two weeks. After two weeks the tooth was opened, instrumented and irrigated (fig.2)

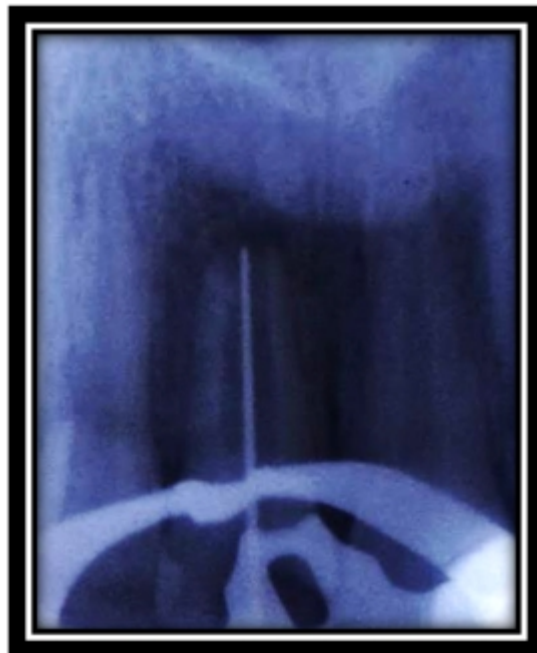

Fig. 2

MTA angelus is the MTA used here. It was mixed to a paste consistency with sterile water and delivered to the canal using the messing gun in about 4mm thickness. A hand plugger was used to condense the MTA at the apex. A moist cotton pellet was sealed inside to allow the MTA to set. (Fig 3)

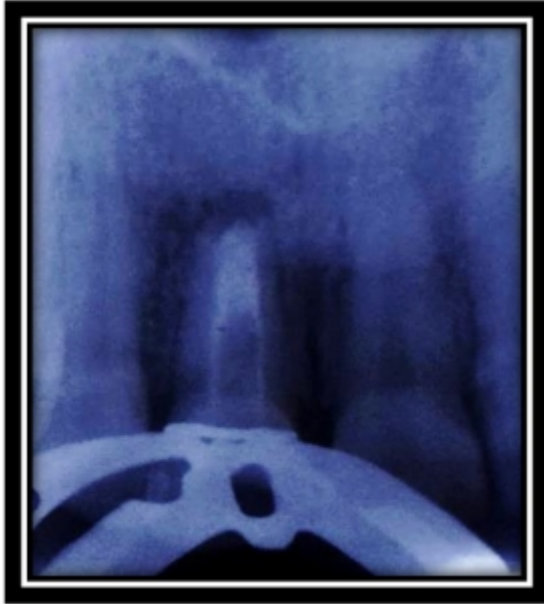

Fig 3

Remaining canal was sealed with thermoplasticised gutta- percha the next day. A corono-radicular composite restoration sealed the access preparation. (Fig 3). Six months follow up demonstrated a radiographic decrease in the periapical radiolucency.

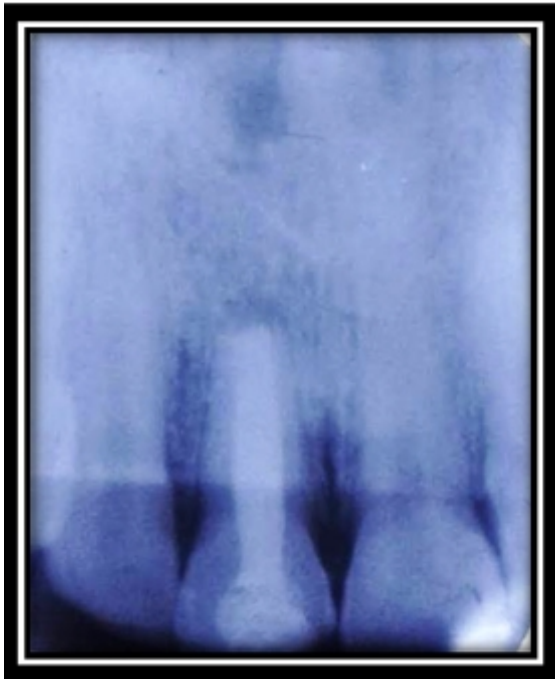

Fig 4

The tooth was asymptomatic, and clinically functional.

DISCUSSION

Calcium hydroxide has been used with great success to form an apical hard tissue barrier in immature open apices⁷. The time interval for calcium hydroxide apexification has been reported to be variable, ranging from 3-24 months⁸. In this case, the speedy barrier formation could be attributed to the frequent calcium hydroxide dressing replacement⁹. The barrier produced by calcium hydroxide apexification has been reported to be incomplete having Swiss cheese appearance and can allow apical micro leakage. Thus a permanent root canal filling is still mandatory. Pulp revascularization remains a good treatment option for such cases but the patient was not agreeable to the time constraints. So, one step apexification with MTA was decided for this case. MTA has been widely recommended for plugging open apices^{10,11,12}. It has good apical seal, biocompatibility, pulpal and periodontal tissue regenerating capabilities^{13,14,15,16}. Authors have reported that MTA root fillings placed at the cemental canal limit showed better results than overfilling's^{12,16}. Various materials have been used to prevent MTA extrusion into the periodontal tissues, including hydroxyapatite, collagen, calcium phosphate cement and calcium sulphate¹¹. In this case, the apical stop gained by calcium hydroxide use was used to obtain a dense MTA plug contained within the apical limit of the tooth. The anatomy of the canal dictated the use of a plastic filling material. Access was sealed with composite restoration starting from 3 mm below the cervical line to reinforce this tooth against fracture. The six- month follow up showed clinical and radiographic signs of healing. Long term follow up is however necessary to ensure success, especially since this therapy would probably increase chances of tooth fracture.¹⁷

CONCLUSION

In this case, MTA helped to make an apical barrier within the immature necrotic maxillary central incisor and showed a progressive clinical and radio-

graphic success. The use of MTA apical plug after gaining a matrix with the use of calcium hydroxide showed a positive clinical outcome for the immature tooth. The use of adequate irrigants along with calcium hydroxide as an intracanal medicament aided in the periapical healing of the chronic apical periodontitis.

REFERENCES

1. Brett Rosenberg et al The effect of calcium hydroxide root filling on dentin fracture strength: *Dent Traumatol*; 2007, 23 (1), p.26-29.
2. Sheehy EC, Roberts GJ, Use of calcium hydroxide for apical barrier formation and healing in non-vital immature permanent teeth: a review: *Braz. Dent J.*; 1997, 11, 183(7):p.241-6
3. Rafter M, Apexification: a review: *Dent. Traumatol*; 2005, 21, p.1-8
4. Stephen Cohen, Kenneth M. Hargreaves: *Pathways of the pulp*, St Louis, Missouri, Mosby 2006, p.622.
5. Shabhahang S et al. A comparative study of root induction using osteogenic protein-1, calcium hydroxide and mineral trioxide aggregate in dogs: *J Endod*; 1999, 25:p.1-5.
6. Holland R et al. Influence of the type of vehicle and limit of obturation on apical and periapical tissue response in dogs teeth after root canal filling with mineral trioxide aggregate: *J Endod*; 2007, 33(6), p.693-7.
7. Steinig TH, Regan JD, Guttmann JL. The use and predictable placement of Mineral Trioxide Aggregate in one-visit Apexification cases: *Aust. Endod J.* 2003. 29(1), p.34-42.
8. Andreasen Jo et al, Long-term calcium hydroxide as a root canal dressing may increase the risk of root fracture: *Dent Traumatol*; 2002, 18(3), p.134-7.
9. Abbot P. Apexification with calcium hydroxide-when should the dressing be changed? Case for regular dressing's changes: *Aust. Endod J*; 1998, 24, p.27-32.
10. Giuliani V, Baccetti T, Pace R, Pagavino G. The use of MTA in teeth with necrotic pulps and open apices: *Dent Traumatol.*; 2002, 18(4):p.217-21.
11. Ham KA, Witherspoon DE, Guttmann JL, Ravindranath S, Gait TC, Opperman LA. Preliminary evaluation of BMP-expression and histological characteristics during apexification with calcium hydroxide and mineral trioxide aggregate: *J Endod.*; 2005, 31(4):p.275-9.
12. Hachmeister DR, Schindler WG, Walker WA 3rd, Thomas DD. The sealing ability and retention characteristics of mineral trioxide aggregate in a model of apexification: *J Endod.*; 2002, 28(5):p.386-90.
13. Torabinejad M, Watson TF, Pitt FTR. The sealing ability of a mineral trioxide aggregate as a retrograde root filling material: *J Endod.*; 1993, 19: p.59-65.
14. Torabinejad M, Chivian N. Clinical applications of mineral trioxide aggregate: *J Endod.*; 1999, 25: p.197-205.
15. Simon, F. Rilliard, A. Berdal & P. Machtou. The use of mineral trioxide aggregate in one-visit apexification treatment: a prospective study: *Int. Endod. J.*; 2007, 40(3) p.186-97
16. J. Camilleri, T. R. Pitt Ford Mineral trioxide aggregate: a review of the constituents and biological properties of the material: *Int. Endod. J.*; 2006, 39 (10) p.747-54.
17. Jens Ove Andreasen et al Comparison of fracture resistance in root canals of immature sheep teeth after filling with Calcium hydroxide or MTA: *Dent. Traumatol*; 2006, 22 (3) p.154-6.