

CONSERVATIVE MANAGEMENT OF A PERIODONTALLY COMPROMISED TOOTH - A CASE REPORT ON BICUSPIDIZATION WITH TWO YEAR FOLLOW UP.

Authors:

Noorudeen AM¹
Mathew T Joy²
Sanjeev R³
Bijoy John⁴

¹ Professor & Head
Department of Periodontics
Indira Gandhi Institute of Dental Sciences
Kothamangalam, Ernakulam Dt., Kerala.

² Senior Lecturer
Department of Periodontics
Indira Gandhi Institute of Dental Sciences
Kothamangalam, Ernakulam Dt., Kerala.

³ Professor
Department of Periodontics
Indira Gandhi Institute of Dental Sciences
Kothamangalam, Ernakulam Dt., Kerala.

⁴ Reader
Department of Periodontics
Indira Gandhi Institute of Dental Sciences
Kothamangalam, Ernakulam Dt., Kerala.

Corresponding Author:

Dr. Mathew T. Joy
Senior Lecturer
Department of Periodontics
Indira Gandhi Institute of Dental Sciences
Kothamangalam, Ernakulam Dt., Kerala.
E mail: joy.mathew23@gmail.com

ABSTRACT

The mandibular molars are first teeth to erupt in oral cavity and therefore are having high caries susceptibility index, which actually necessitates cautious implementations of oral hygiene measures. Any deprivation in the maintenance may lead to serious problem like furcation involvement. Bisection/bicuspidization is the separation of mesial and distal roots of mandibular molars along with its crown portion, where both segments are then retained individually. A multidisciplinary treatment procedure for such clinical situations that includes restorative dentistry, endodontics, periodontics, and prosthodontics is necessary to preserve the teeth in whole or in part. These teeth can act as independent single units of mastication or as abutments in simple fixed bridges. This clinical report has sought to systematically review the multidisciplinary treatment procedure for periodontally compromised mandibular molar by bicuspidization and total rehabilitation using the double crowns technique.

Keywords: Bicuspidization, furcation defect, molars.

J Odontol Res 2015;3(1)35-39.

INTRODUCTION

The treatment, management and long-term retention of mandibular molar teeth exhibiting furcation invasions have always been a challenge to the discerning general dentist or dental specialist. Continued periodontal breakdown may lead to total loss of tooth unless these defects can be repaired or eliminated and health of the tissues restored.¹

Term furcation involvement refers to the invasion of the bifurcation and trifurcation of the multirooted teeth by the periodontal disease.² Though, furcation involvement is the most common phenomenon in mandibular molars it requires immediate attention with respective management.³ Advances in dentistry, as well as the increased desire of patients to maintain their dentition, have led to treatment of teeth that once would have been removed.⁴

Bicuspidization is a valuable treatment option to save multirooted teeth having a hopeless prognosis.³ Bisection/bicuspidization technique is the separation of mesial and distal roots of mandibular molars along with its crown portion, where both segments are then retained individually. It is usually performed in Grade II or III furcation defects of mandibular molars, to remove the irritants under the fornix and to obtain two single-rooted teeth for crowning as premolar.⁵

The prognosis of the tooth with hemisection / bicuspidization depends on the supporting bone, the restorative treatment plan, and the oral hygiene of the patient. Thus tooth separation / bicuspidization procedures are used to preserve as much tooth structure as possible rather than sacrificing the whole tooth.⁶

In order to carry out this present day mandate, periodontally diseased teeth with severe bone loss at furcation area may well be retained by separation of their roots. This article describes a simple procedure for bicuspidization in mandibular molar and its subsequent restoration.

CASE REPORT

A 55 year old male patient came to the department of periodontics with the chief complaint of pain in left lower back tooth region since 3 months. On exami-

nation 36 revealed a Grade III furcation involvement. On probing the area, there was 7mm deep periodontal pocket in the buccal aspect around the furcation area (Fig.1). Class II caries with no periapical pathology was detected in the distal aspect. On radiographic examination, intra oral periapical radiographs (IOPA) confirmed Class III furcation involvement (Glickman's classification) with evident bone loss in the furcation area (fig. 2). The mesial and distal roots have sufficient bone support.

Based on above findings oral prophylaxis was performed followed by administration of systemic antibiotics for five days.

A routine blood hemogram was advised, and after ascertaining it was within normal limits, treatment plan was formulated. Root canal treatment, subsequent bicuspidization and restoration of tooth with PFM crown was planned (fig. 3).

Accordingly access cavity was prepared and the working canal length was determined and the canals were biomechanically prepared using step back technique. Lateral condensation technique was followed in the mesial and the distal canal for obturation. Damaged tooth structure was reconstructed with silver amalgam core. The occlusal table was minimized to redirect the force along the long axis of each root.

Under local anesthesia, full thickness flap was raised with conventional flap procedure from distal aspect of 35 to mesial aspect of 37 on both buccal and lingual sides. A vertical cut method was used to separate the crown of 36. A long shank straight fissure diamond bur was used to make vertical cut towards the bifurcation area. Single molar is now separated into two crowns (fig. 4, 5). The furcation area was trimmed to ensure that no residual debris were present that could cause further periodontal irritation.

Curettage of the furcation area was done, which became accessible on separation. Sutures were placed between mesial, distal and mid-portion of the separated tooth. Periodontal dressing was placed. Systemic antibiotics and analgesics were prescribed and post operative instructions were given.

Patient was recalled after ten days for suture removal followed by crown preparation on two separated halves of 36. Impression was recorded and temporization done. After one week, two separate PFM crowns were cemented on mesial and distal half of the tooth (fig. 6).

Case was followed up postoperatively every six months till date.

DISCUSSION

Periodontitis is considered as subgingival inflammation caused by bacterial infection. It affects the periodontal supporting tissues including periodontal ligament, cementum, and alveolar bone. Periodontitis affects the junction of multi-rooted tooth, initially with tissue destructions then gradually with further bone loss and eventually end up with furcation involvement.⁷

The mandibular molars are first teeth to erupt in oral cavity and therefore are having high caries susceptibility index, which actually necessitates cautious implementations of oral hygiene measures. Any deprivation in the maintenance may lead to serious problem like furcation involvement.⁷

Diagnosis and treatment of furcation involvement is a challenge. Management of molars with furcation involvement represents one of the major problems in clinical periodontology. Both prognosis and choice of therapy depend on the degree of furcation involvement.⁸ Root surfaces facing the furcation area of mandibular molars are concave, resulting in a wider mesiodistal osseous chamber than either the buccal or lingual furcation opening.²

Farshchian and Kaiser were the first to depict the successful implementation of bicuspidization or molar bisection procedures in the management of severe furcation involvements.⁷ They stated that the success of bicuspidization depends on three factors:^{1,4,7,9}

- (i) stability of, and adequate bone support for, the individual tooth sections;
- (ii) absence of severe root fluting of the distal aspect of the mesial root or mesial aspect of the distal root;
- (iii) adequate separation of the mesial and distal

roots, to enable the creation of an acceptable embrasure for effective oral hygiene^{1,4,7,9}

Indications of bicuspidization^{3,9,10}

- Severe bone loss affecting one or more roots untreatable with regenerative procedures.
- Class II or III furcation invasions or involvements.
- Severe recession or dehiscence of a root.
- Root caries of the furcation area.
- Severe root proximity inadequate for a proper embrasure space.
- Root trunk fracture or decay with invasion of the biological width.

Contraindications of bicuspidization^{3,9,10}

- Poor oral hygiene status
- Systemic factors
- Unfavorable tissue architecture
- Retained roots endodontically untreatable
- Excessive deepening of pulp chamber floor
- Severe root resorption
- Presence of a cemented post in the remaining root

Advantage of the amputation, hemisection or bisection is the retention of some or the entire tooth. However, the disadvantage is that the remaining root or roots must undergo endodontic therapy and the crown must undergo restorative management.^{1,3}

Bicuspidization procedures with double crowns may be considered as a suitable alternative to extraction in multi-rooted teeth with hopeless prognosis.⁷ The clinical outcome and long-term performance of bicuspidization and double crowns are predictable with high success rates. Bicuspidization with definitive prosthetic rehabilitation have received acceptance as a traditional and reliable dental treatment.^{3,7}

CONCLUSION

The management of furcation involvement presents one of the greatest challenges in periodontal therapy. The decision for a specific treatment for a periodontitis- affected furcation certainly depends

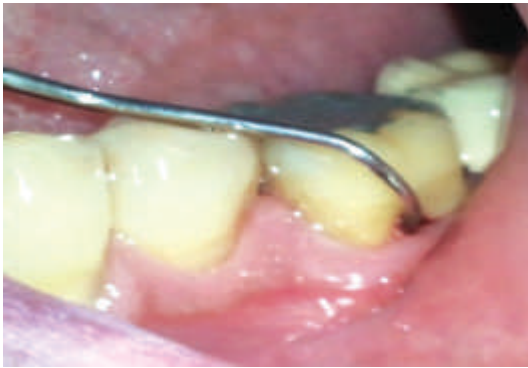

Fig.1 Pre-operative view showing Grade III furcation in relation to 36

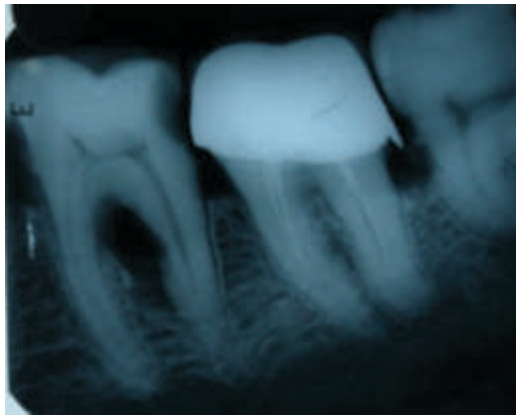


Fig.2 Preoperative radiograph

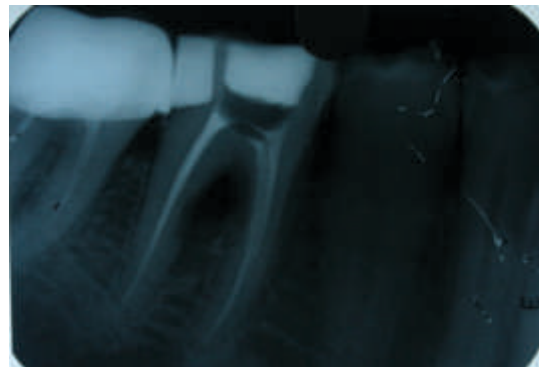


Fig.3 Preoperative radiograph showing well obturated root canal in relation to 36

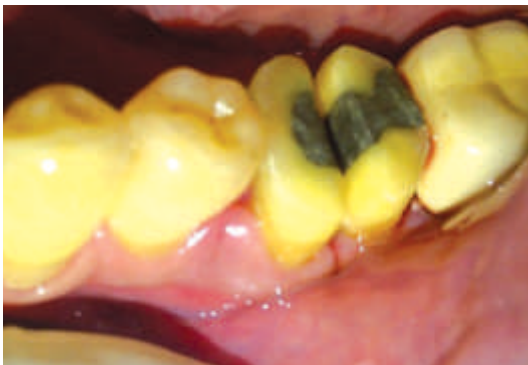

Fig.4 Bicuspidization -A vertical cut made toward the bifurcation area for hemisection

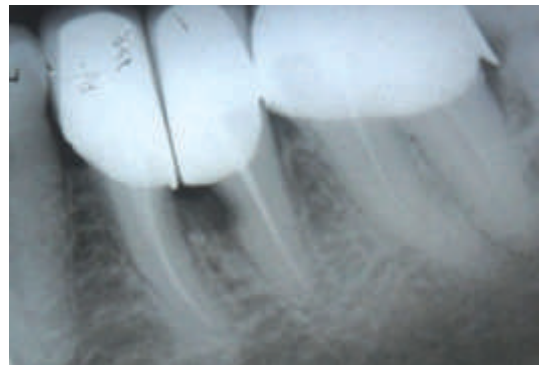


Fig.5 Post operative radiograph

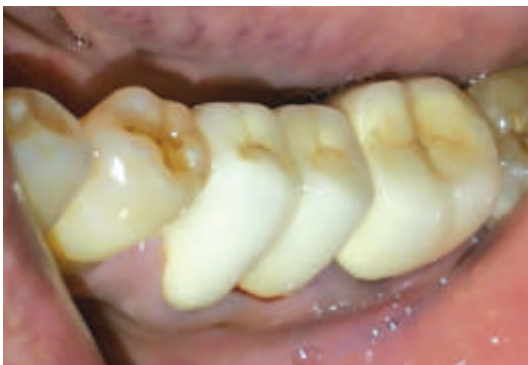

Fig.6 Crown placed

on several factors. Tooth type and degree of furcation involvement may be regarded by the majority of therapists as the most important factors influencing the decision for one or other treatment mode.

The prognosis of the tooth with bicuspidization depends on the supporting bone, the restorative treatment plan, and the oral hygiene of the patient. With improvement in the dental procedures and materials in both periodontics and endodontics leading to more sophisticated therapy, teeth at marginal prognosis has provided the opportunity for patients to maintain a functional dentition for life time.

REFERENCES

1. Dalkiz M, Cilingir A, Beydemir B. Bicuspidization: a case report. *Mart* 2008; 50:42-5.
2. Gupta D, Sharma P, Khandelwal S. Salvage periodontally compromised teeth through bicuspidization-a case report. *IJIRD* 2011;1(2):19-29.
3. Kumar P, Singh V, Kumar A, Singh H. Imperative role of prosthodontist in the management of furcation defect of mandibular molar. *e-Journal of Dentistry* 2012;2(2):176.
4. Mantri V, Maria R, Kamat S, Raut AW. Root Amputation: case reports and review. *Endontology* 2013;25(2):89-95.
5. Arabaci T, Yasin I, Hasan G. Treatment of a complicated iatrogenic furcation perforation in a mandibular molar with bicuspidization technique: a case report-*JMUIHS* 2012;2(3):130.
6. Javali M A, Safeena, Ayesha H. Root resection of maxillary first molar: a case report. *Heal talk* 2012;4(4):20-1.
7. Sahoo S, Sethi K, Kumar P, Bansal A. Management of periodontal furcation defects employing molar bisection- a case report. *Dental hypothesis* 2013;4(3):97-101.
8. Romito GA, Pustiglioni FE - Biometric study of furcation area of first maxillary molars. *Braz dent J* 2004;15(2):155-8.
9. Kaur J, Bala S, Sharma N. Bicuspidization restoration of split molar: a case report-*Indian Journal of applied research* 2013;3(7):78-80.
10. Quader SM, Alam MS, Khan MO, Moral AA. Hemisection of a mandibular molar-*Update Dent.Coll.* 2011;1(1):18-22.